

DR NAJJIA ASHRAF

**M.B.B.S(DOW),MD(SRILANKA),MSc(CLINICAL
DERMTOLOGY,KINGS COLLEGE LONDON)**

**CONSULTANT DERMATOLOGIST,COSMETOLOGIST
AND LASER THERAPIST.**

WWW.DRNAJJIAASHRAF.COM

DRNAJJIAASHRAF@HOTMAIL.COM

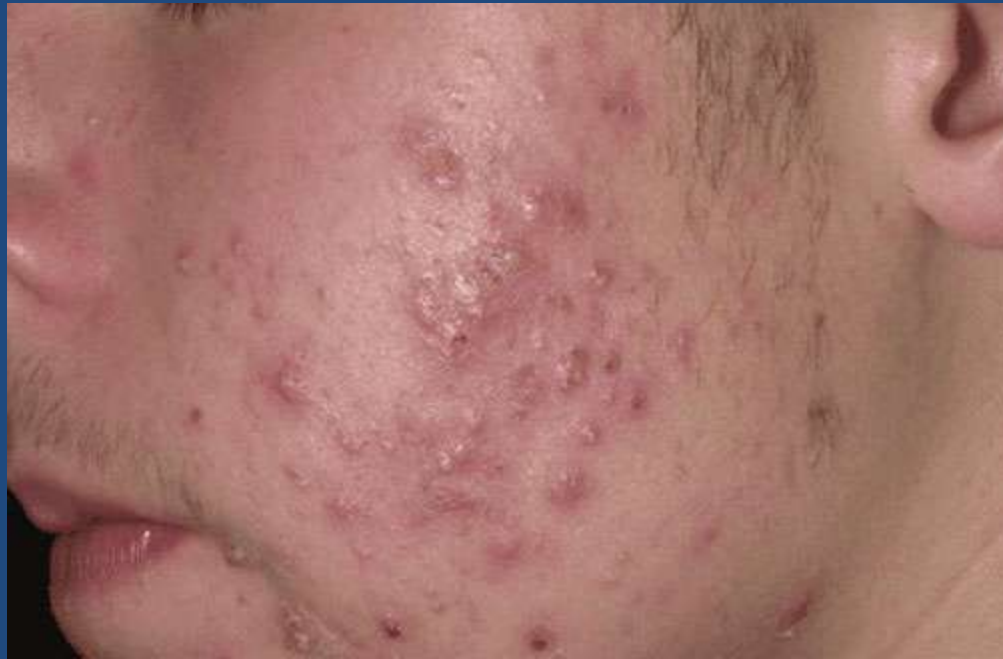

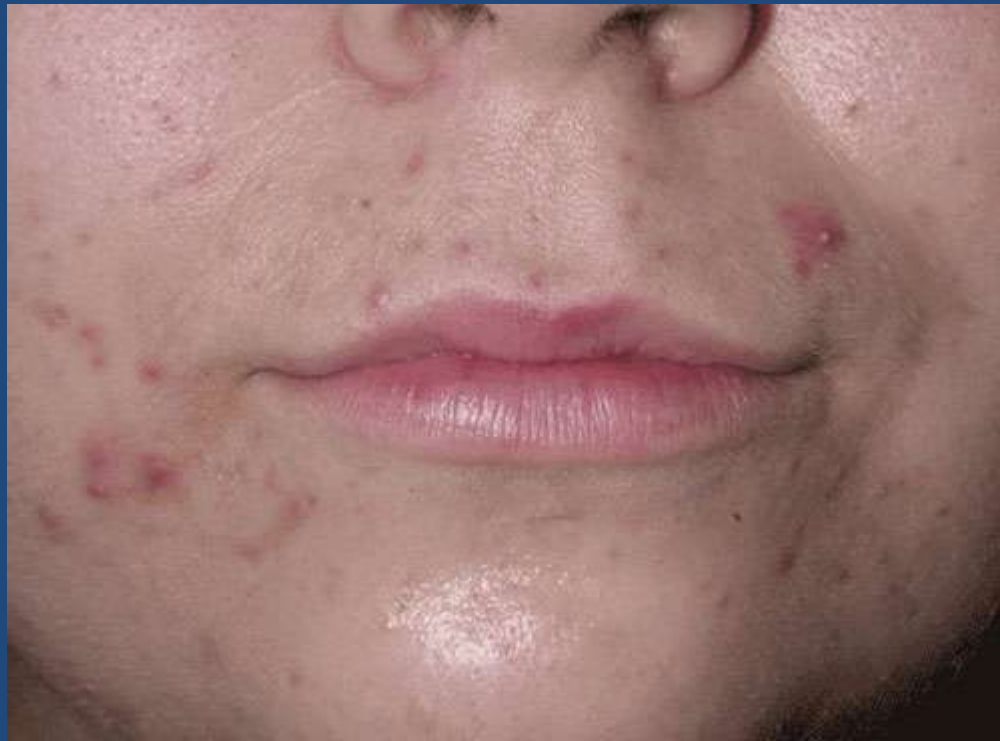Acne – Common Issues and Treatment











ACNE VULGARIS

DEFINITION

- Acne Vulgaris is a common chronic inflammatory disorder of the pilosebaceous follicles

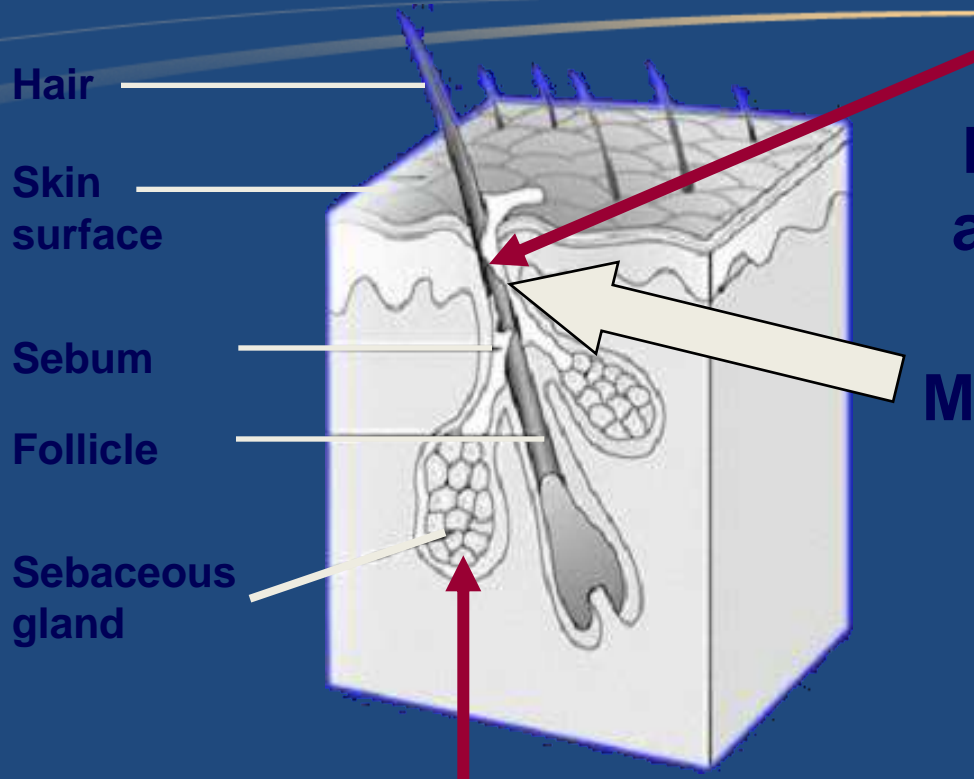
Zaidi, ZH, 2005, *Manual of Dermatology*, International composers and printers, Karachi.

AETIOLOGY OF ACNE VULGARIS

Four major factors are involved

- Increased production of sebum
- Ductal hypercornification; histologically seen as micro-comedones
- Colonization of the duct with *P.acnes*
- Inflammation

PATHOGENESIS



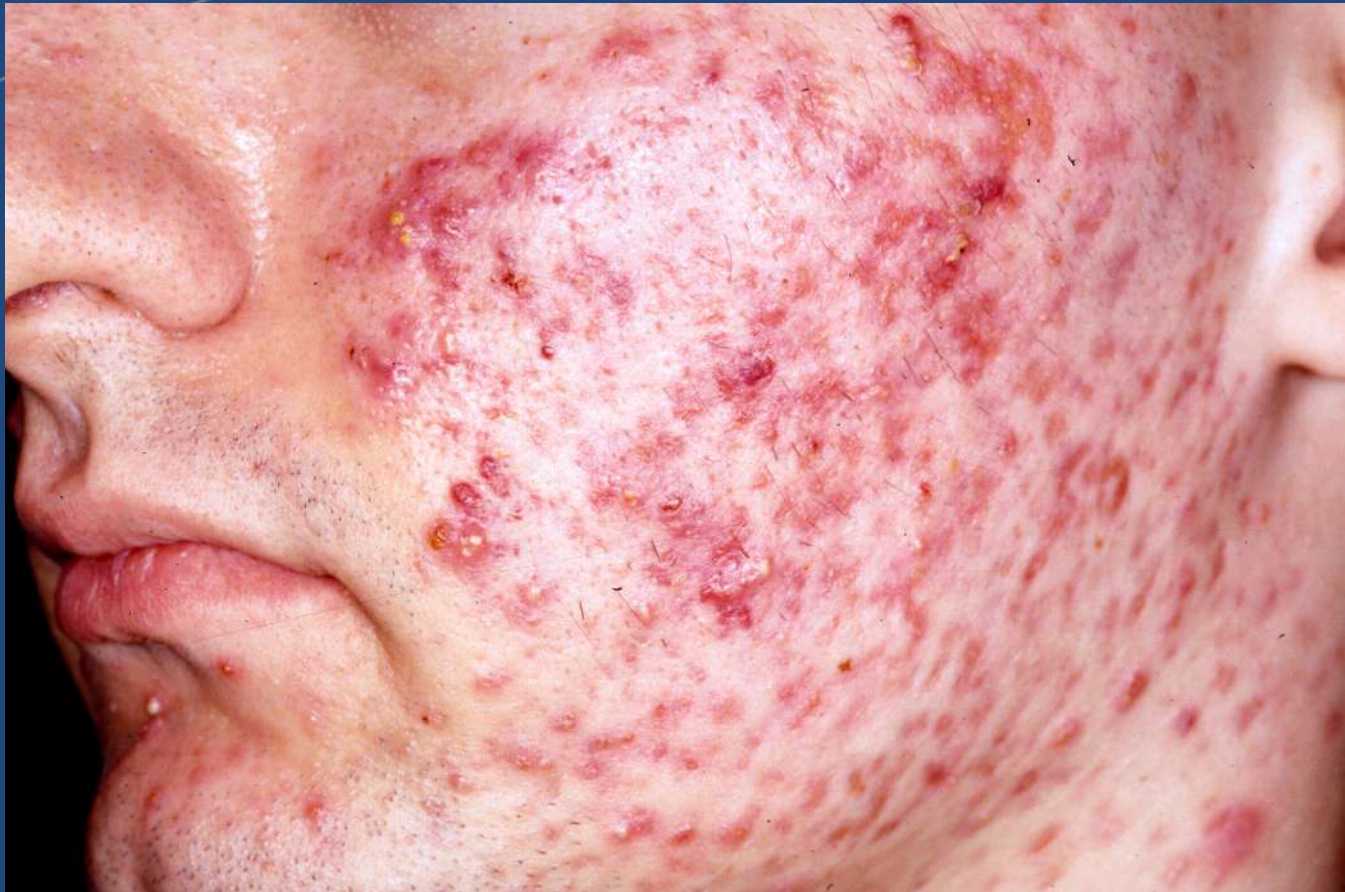Sebaceous gland activity

Follicular hyperkeratinization and abnormal desquamation

Microcomedo formation, *P acnes* proliferation, inflammation/immune hypersensitivity



Dermal changes that may lead to scarring



FACTORS INFLUENCING ACNE VULGARIS

- Diet: Scientific proof is lacking on diet being responsible for acne
- Premenstrual flare: Possibly related to a premenstrual change in the hydration of the pilosebaceous epithelium
- Sweating: Causes aggravation in acne
- Occupation: Certain occupations like those dealing with oil predispose people to develop acne

Burns, T, Breathnach S et al, 2004, *Textbook of dermatology*, Blackwell, Massachusetts

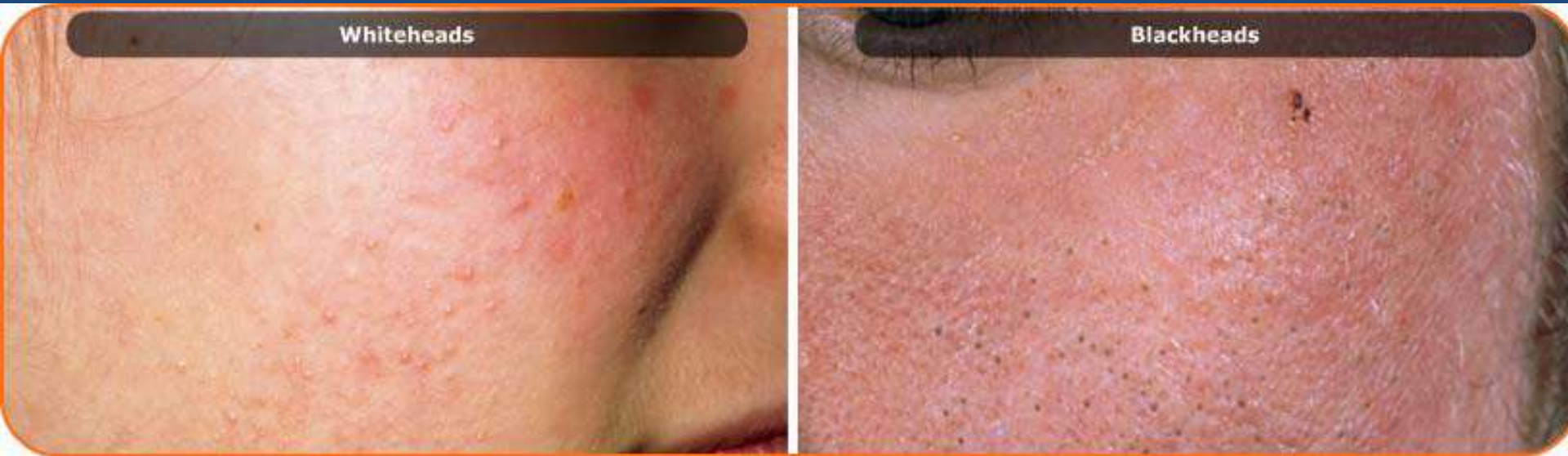ACNE LESION

May present in the following forms:

- Comedo
 - Closed comedo : whitehead
 - Open comedo : blackhead
- Papule – superficial red bump
- Pustule – superficial red bump with pus
- Nodule/cyst - tender, painful, deep inflammatory lesion containing pus and/or blood

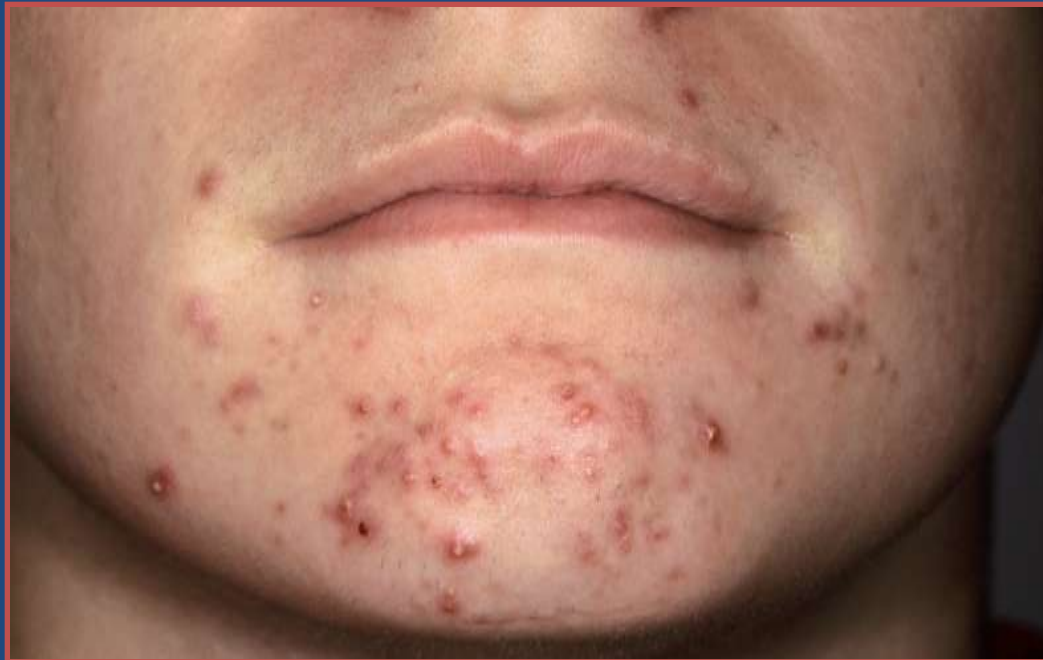CLOSED AND OPEN COMEDONES

- Closed comedones are whitish or yellow in colour; they occur as small papules often with a central point or elevation
- Open comedones are black in colour; the black colour is perhaps due to the oxidation of keratin, or due to the presence of melanin



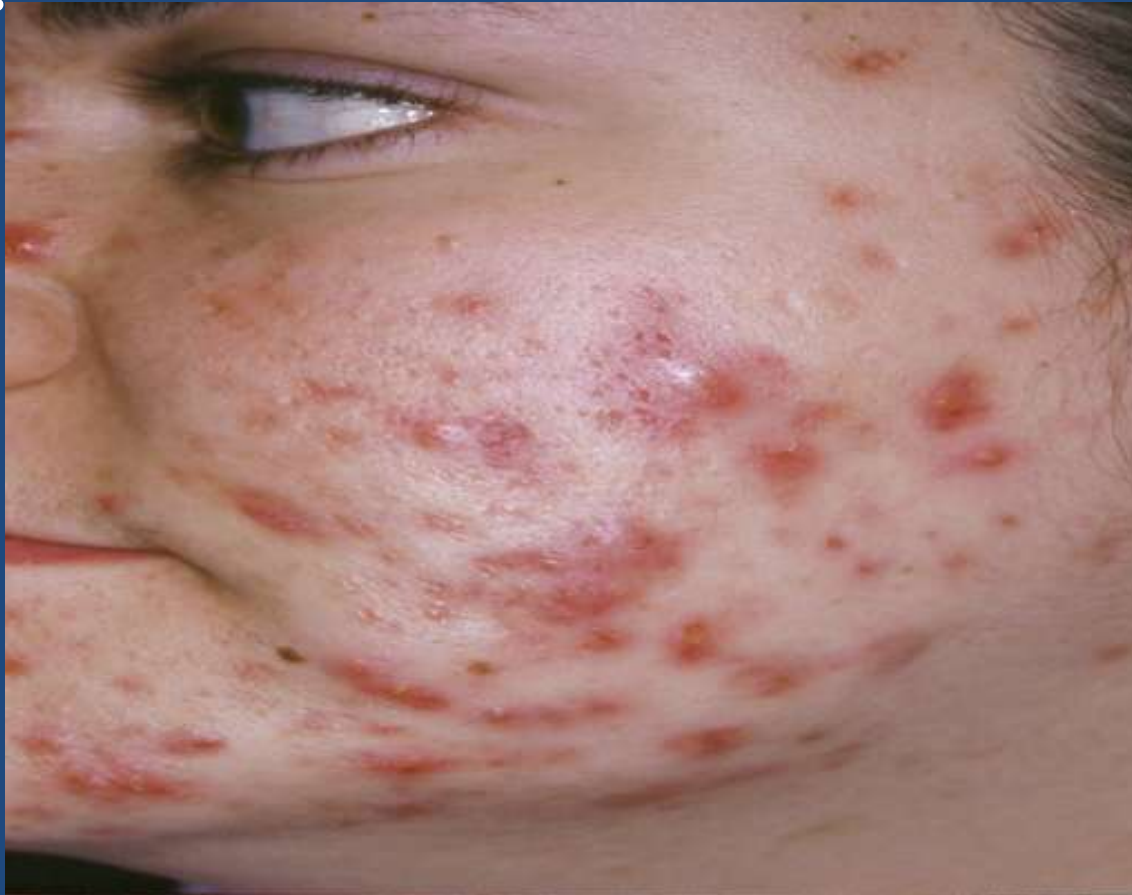PAPULAR AND PUSTULAR ACNE

Papules and pustules are relatively superficial lesions, these develop on a red base it may be itchy or painful. They resolve over the course of a few days. New lesions may arise at the same place in a number of cases.



NODULAR AND CYSTIC ACNE

Nodules and cysts are deep-seated lesions; they are less common than the papules and pustules



CLINICAL VARIANTS OF ACNE

- Adolescent acne
- Post-adolescent acne
- Infantile acne
- Acne excoriee
- Drug induced acne
- Occupational acne
- Occlusive acne
- Tropical acne

Zaidi, ZH,2005, *Manual of Dermatology*, International composers and printers, Karachi

TREATMENT

MILD ACNE:

Topical treatment:

i. Keratolytic drugs

- Benzoyl peroxide is an effective antibacterial and is comedolytic. It is sometimes combined with some group of antibacterials
- Retinoic acid is used as a keratolytic

ii. Topical antibiotics:

- 1% Clindamycin (most effective), 2% erythromycin, and tetracycline

iii. Other modalities

- Ultraviolet light.
- Many patients note that their acne improves during summer. Ultraviolet B is used therapeutically in doses to produce erythema and consequently desquamation of skin

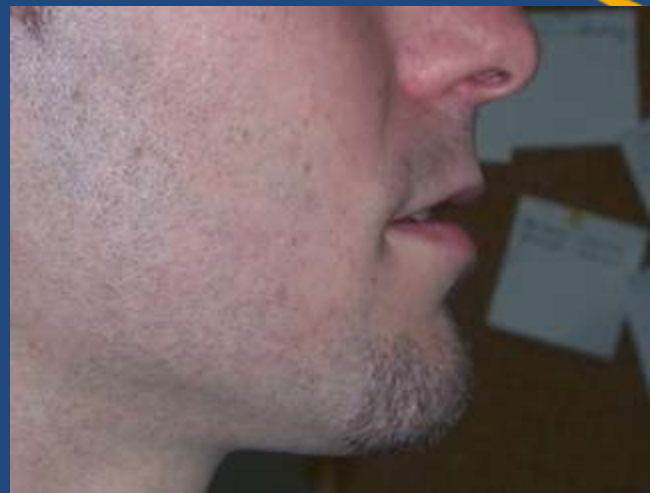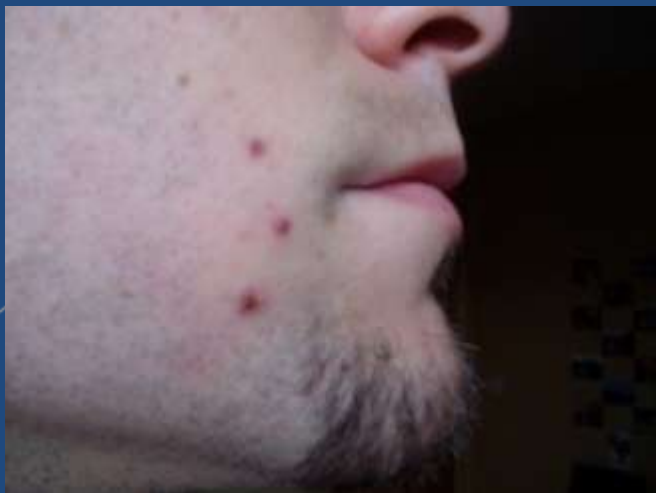MODERATE TO SEVERE ACNE: Choice varies patient to patient

i. Systemic antibiotics:

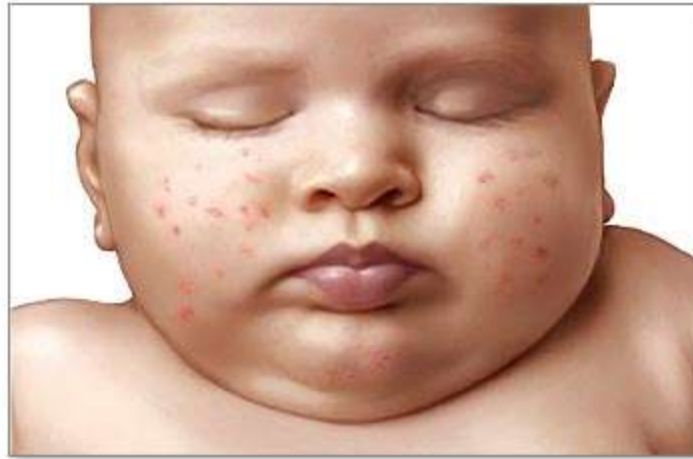- Tetracycline, erythromycin, cotrimoxazole, flucloxacillin are effective, as they concentrate in the pilosebaceous apparatus
- Minocycline in a dose of 50mg twice daily

ii. Systemic Retinoid therapy:

- 13-cis-retinoic acid therapy (Roaccutane). It is the treatment of choice in nodulocystic acne, for acne unresponsive to adequate conventional therapy and for acne causing scarring



BEFORE AND AFTER TREATMENT



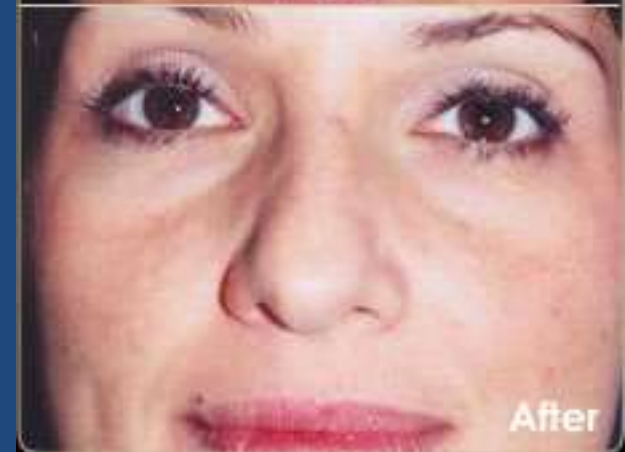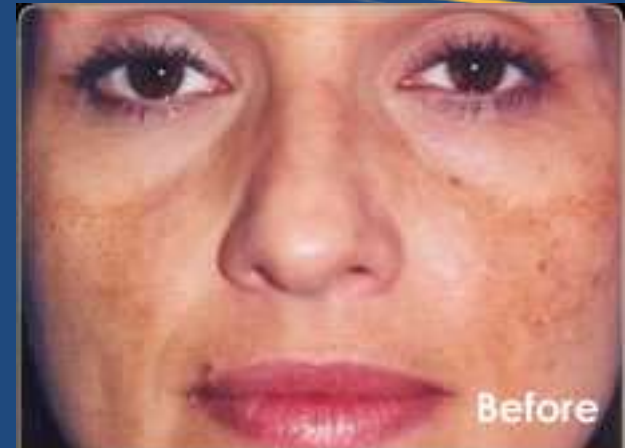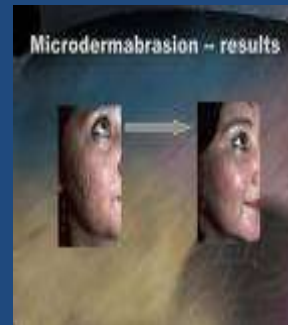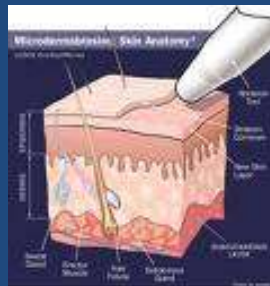
Baby acne

iii. Other modalities

- Hormonal therapy
- Intralesional triamcinolone
- Dermabrasion and collagen injection
- Cryotherapy

MICRODERMABRAISION

- Mechanical exfoliation with adjustable suction, to remove outer most layer of skin cells.
- Non invasive procedure
- Decrease apperance of superficial hyperpigmentation, photodamage ,diminish fine lines, wrinkles and shallow acne scars which helps to even out texture.





*And the most
important:*

*Life doesn't
end today...*





THANK YOU.....

CONTACT DETAILS

- NATIONAL MEDICAL CENTRE
- DHA-1, KALAPUL, KARACHI

- SKIN AND LASER BY SHAHNAZ
- ZAMZAMA LANE 6, OPP BUTLER CAFÉ

- WWW.DRNAJJIAASHRAF.COM

- 0300-2783284